Nurses Content
Downloaded from nursescontent.com

Sensory Organs

Anatomy & Physiology

Eye, ear, nose, tongue and skin

For educational purposes only.

Sensory Organs - Applied Anatomy Notes for B.Sc. Nursing

1. Introduction

Sensory organs are specialised structures that detect changes in the internal and external environment and transmit information to the nervous system.

They help the body recognise light, sound, smell, taste, touch, temperature, pressure and pain.

Five Major Sensory Organs

1. Eye - Organ of vision.
2. Ear - Organ of hearing and balance.
3. Nose - Organ of smell.
4. Tongue - Organ of taste.
5. Skin - Organ of touch and general sensation.

Functions of Sensory Organs

- Detect environmental changes.
- Receive sensory stimuli.
- Transmit sensory information to the brain.
- Help maintain balance and coordination.
- Protect the body by detecting harmful stimuli.
- Support communication and interaction with the environment.

2. Eye - Organ of Vision

Definition

The eye is a specialised sensory organ responsible for vision. It detects light and converts it into nerve impulses that are interpreted by the brain.

Location

- Located in the orbital cavities of the skull.
- Each eye is protected by the bony orbit, eyelids and surrounding tissues.
- The optic nerve connects the eye to the brain.

Nurses Content
Downloaded from nursescontent.com

Structure of the Eye

The eyeball is approximately spherical and has three main coats or layers.

A. Outer Fibrous Layer

It consists of two structures:

1. Sclera
   - Tough, white outer covering of the eyeball.
   - Protects the eye and maintains its shape.
   - Provides attachment to extraocular muscles.
2. Cornea
   - Transparent, curved anterior portion of the eye.
   - Allows light to enter.
   - Provides most of the eye's refractive power.

B. Middle Vascular Layer (Uvea)

It consists of three parts:

1. Choroid
   - Highly vascular and pigmented layer.
   - Supplies nutrients and oxygen to the retina.
   - Absorbs excess light to reduce internal reflection.
2. Ciliary Body
   - Contains the ciliary muscle and ciliary processes.
   - Helps control the shape of the lens for near and distant vision.
   - Produces aqueous humour.
3. Iris
   - Coloured part of the eye.
   - Contains circular and radial muscles.
   - Controls pupil size and regulates the amount of light entering the eye.

C. Inner Nervous Layer - Retina

- Innermost layer of the eyeball.
- Contains photoreceptor cells called rods and cones.
- Converts light into electrical nerve signals.

Rods

- Responsible for vision in dim light.
- Help with peripheral vision.

Nurses Content
Downloaded from nursescontent.com

- Do not provide colour vision.

Cones

- Responsible for colour vision.
- Provide sharp and detailed vision.
- Function best in bright light.

Important Parts of the Retina

Structure

Function

Macula lutea

Area responsible for central vision

Fovea centralis

Area of highest visual acuity; contains a high concentration of cones

Optic disc

Point where the optic nerve exits; has no photoreceptors and forms the blind spot

Internal Structures of the Eye

1. Lens
   - Transparent, biconvex structure behind the iris.
   - Focuses light onto the retina.
   - Changes shape during accommodation.
2. Aqueous Humour
   - Clear fluid present in the anterior part of the eye.
   - Located in the anterior and posterior chambers.
   - Nourishes the cornea and lens.
   - Helps maintain intraocular pressure.
3. Vitreous Humour
   - Transparent, gel-like substance filling the vitreous chamber behind the lens.
   - Helps maintain the shape of the eyeball.
   - Supports the retina.
4. Pupil
   - Opening in the centre of the iris.
   - Regulates the amount of light entering the eye.

Nurses Content
Downloaded from nursescontent.com

Accessory Structures of the Eye

- Eyebrows: Help prevent sweat from entering the eyes.
- Eyelids: Protect the eyes from injury and excessive light.
- Eyelashes: Help prevent dust and foreign particles from entering.
- Conjunctiva: Thin mucous membrane covering the anterior sclera and lining the inner eyelids.
- Lacrimal apparatus: Produces and drains tears to lubricate and protect the eye.
- Extraocular muscles: Move the eyeball in different directions.

Extraocular Muscles

There are six main muscles that move each eyeball:

1. Superior rectus
2. Inferior rectus
3. Medial rectus
4. Lateral rectus
5. Superior oblique
6. Inferior oblique

Pathway of Vision

1. Light enters through the cornea.
2. Passes through the aqueous humour.
3. Enters through the pupil.
4. Passes through the lens.
5. Travels through the vitreous humour.
6. Reaches the retina.
7. Photoreceptors convert light into electrical signals.
8. Signals travel through the optic nerve.
9. Visual information reaches the visual cortex in the occipital lobe.

Clinical Importance

- Myopia: Difficulty seeing distant objects clearly.
- Hypermetropia: Difficulty seeing near objects clearly.
- Astigmatism: Blurred vision due to irregular curvature of the cornea or lens.
- Cataract: Opacity of the lens.
- Glaucoma: Group of disorders involving optic nerve damage, often associated with raised intraocular pressure.
- Conjunctivitis: Inflammation of the conjunctiva.

- Retinal detachment: Separation of the retina from its supporting tissues.

3. Ear - Organ of Hearing and Balance

Definition

The ear is a sensory organ responsible for hearing and maintaining body balance.

Location

The ears are located on both sides of the head within the temporal bone region.

Parts of the Ear

The ear is divided into three main parts:

1. External ear
2. Middle ear
3. Inner ear

A. External Ear

The external ear collects sound waves and directs them towards the eardrum.

Parts:

1. Pinna (Auricle)
   - Visible external part of the ear.
   - Made mainly of elastic cartilage covered by skin.
   - Collects sound waves.
2. External Auditory Canal
   - Passage that carries sound waves towards the tympanic membrane.
   - Contains hairs and ceruminous glands.
   - Cerumen (earwax) helps protect the canal.
3. Tympanic Membrane (Eardrum)
   - Thin membrane separating the external and middle ear.
   - Vibrates in response to sound waves.

B. Middle Ear

The middle ear is an air-filled cavity located in the temporal bone.

Auditory Ossicles

The middle ear contains three small bones:

Bone

Function

Nurses Content
Downloaded from nursescontent.com

Malleus

Receives vibrations from the tympanic membrane

Incus

Transmits vibrations from malleus to stapes

Stapes

Transfers vibrations to the oval window

These are the smallest bones in the human body.

Other Structures

1. Eustachian Tube (Auditory Tube)
   - Connects the middle ear to the nasopharynx.
   - Equalises air pressure on both sides of the tympanic membrane.
2. Oval Window
   - Receives vibrations from the stapes.
   - Transmits vibrations into the inner ear.
3. Round Window
   - Allows pressure waves within the cochlea to be accommodated.

C. Inner Ear

The inner ear is located within the petrous part of the temporal bone.

It consists of the bony and membranous labyrinths.

Main Structures

1. Cochlea
   - Spiral-shaped structure.
   - Contains the sensory organ for hearing, called the organ of Corti.
   - Converts sound vibrations into nerve impulses.
2. Vestibule
   - Central part of the bony labyrinth.
   - Contains the utricle and saccule.
   - Detects linear acceleration and head position relative to gravity.
3. Semicircular Canals
   - Three canals arranged approximately at right angles.
   - Detect rotational or angular movements of the head.
   - Help maintain dynamic balance.

Nurses Content
Downloaded from nursescontent.com

Mechanism of Hearing

1. Pinna collects sound waves.
2. Sound travels through the external auditory canal.
3. Tympanic membrane vibrates.
4. Ossicles transmit and amplify vibrations.
5. Stapes moves at the oval window.
6. Pressure waves travel through cochlear fluid.
7. Hair cells in the organ of Corti are stimulated.
8. Signals travel through the cochlear branch of the vestibulocochlear nerve (cranial nerve VIII).
9. The brain interprets the signals as sound.

Functions of the Ear

- Hearing.
- Detection of head movement.
- Maintenance of balance.
- Maintenance of posture and spatial orientation.

Clinical Importance

- Otitis externa: Inflammation or infection of the external auditory canal.
- Otitis media: Inflammation or infection of the middle ear.
- Tympanic membrane perforation: Tear or hole in the eardrum.
- Conductive hearing loss: Reduced sound transmission through the external or middle ear.
- Sensorineural hearing loss: Damage involving the inner ear or auditory nerve pathways.
- Vertigo: Sensation of spinning or movement, often associated with vestibular disorders.

4. Nose - Organ of Smell

Definition

The nose is the primary organ of smell. It also serves as the main passage for air entering the respiratory system.

Location

The nose is located centrally on the face and consists of an external part and an internal nasal cavity.

Structure of the Nose

Nurses Content
Downloaded from nursescontent.com

A. External Nose

The external nose consists of:

- Root
- Bridge
- Apex (tip)
- Dorsum
- Nostrils (nares)
- Alae (wings of the nose)

It is supported by nasal bones and cartilages.

B. Nasal Cavity

The nasal cavity extends from the nostrils to the posterior nasal openings called choanae.

It is divided into right and left halves by the nasal septum.

Nasal Septum

The nasal septum consists mainly of:

- Perpendicular plate of ethmoid bone.
- Vomer bone.
- Septal cartilage.

Nasal Conchae

The lateral walls of the nasal cavity contain three nasal conchae:

1. Superior nasal concha
2. Middle nasal concha
3. Inferior nasal concha

These structures increase the surface area and help warm, humidify and filter inhaled air.

Nasal Mucosa

The nasal cavity is lined mainly by respiratory mucosa containing ciliated cells and mucus-producing goblet cells.

Its functions include:

- Trapping dust and microorganisms.
- Warming inspired air.
- Moistening inhaled air.

Olfactory Region

- Located in the roof of the nasal cavity and adjacent upper surfaces.
- Contains olfactory receptor cells.
- Detects odours and sends sensory information through the olfactory nerve (cranial nerve I).

Nurses Content
Downloaded from nursescontent.com

Paranasal Sinuses

Paranasal sinuses are air-filled spaces in the bones surrounding the nasal cavity.

There are four pairs:

1. Frontal sinuses
2. Maxillary sinuses
3. Ethmoidal air cells
4. Sphenoidal sinuses

Functions:

- Reduce the weight of the skull.
- Help warm and humidify inhaled air.
- Produce mucus that drains into the nasal cavity.
- Contribute to voice resonance.

Mechanism of Smell

1. Odour molecules enter the nasal cavity.
2. They dissolve in the mucus covering the olfactory epithelium.
3. Olfactory receptor cells are stimulated.
4. Nerve impulses travel through the olfactory nerve.
5. Signals reach the olfactory bulb and brain.
6. The brain identifies the smell.

Clinical Importance

- Rhinitis: Inflammation of the nasal mucosa.
- Sinusitis: Inflammation of the paranasal sinuses.
- Epistaxis: Bleeding from the nose.
- Deviated nasal septum: Displacement of the nasal septum.
- Anosmia: Loss of the sense of smell.
- Nasal polyps: Non-cancerous growths arising from the nasal or sinus mucosa.

5. Tongue - Organ of Taste

Definition

The tongue is a muscular organ located in the floor of the oral cavity. It is important for taste, speech, chewing and swallowing.

Nurses Content
Downloaded from nursescontent.com

Location

- Situated in the oral cavity.
- Attached to the floor of the mouth.
- Extends towards the oropharynx.

Structure of the Tongue

The tongue is divided into two main parts:

1. Anterior two-thirds (oral part).
2. Posterior one-third (pharyngeal part).

The two parts are separated by a V-shaped groove called the sulcus terminalis.

Parts of the Tongue

1. Apex
   - Tip of the tongue.
   - Helps in speech and manipulation of food.
2. Body
   - Main anterior portion.
   - Contains most of the tongue muscles.
3. Root
   - Posterior part attached to the floor of the mouth and hyoid region.

Papillae of the Tongue

Papillae are small projections on the upper surface of the tongue.

There are four main types:

Type

Characteristics

Filiform

Most numerous; provide friction; generally lack taste buds

Fungiform

Mushroom-shaped; contain taste buds

Circumvallate

Large papillae arranged in a V-shaped row near the sulcus terminalis

Foliate

Fold-like structures on the posterolateral sides; contain taste buds

Nurses Content
Downloaded from nursescontent.com

Taste Buds

Taste buds are sensory structures mainly located in the papillae of the tongue.

They contain specialised taste receptor cells.

Basic Taste Sensations

1. Sweet
2. Salty
3. Sour
4. Bitter
5. Umami (savoury)

Taste perception involves the tongue, palate and other oral structures. The traditional idea of separate, exclusive taste zones on the tongue is incorrect.

Muscles of the Tongue

Tongue muscles are divided into two groups:

A. Intrinsic Muscles

- Superior longitudinal.
- Inferior longitudinal.
- Transverse.
- Vertical.

Function: Change the shape of the tongue.

B. Extrinsic Muscles

- Genioglossus.
- Hyoglossus.
- Styloglossus.
- Palatoglossus.

Function: Move the tongue in different directions.

Nerve Supply of the Tongue

Function and Region

Nerve

General sensation - anterior two-thirds

Lingual nerve (branch of mandibular division of trigeminal nerve, V3)

Taste - anterior two-thirds

Chorda tympani (facial nerve, VII), except vallate papillae

General sensation and taste - posterior one-third

Nurses Content
Downloaded from nursescontent.com

Glossopharyngeal nerve (IX)

General sensation and taste - epiglottic region

Vagus nerve (X)

Motor supply

Hypoglossal nerve (XII), except palatoglossus, supplied by vagus nerve

Functions of the Tongue

- Taste perception.
- Helps in chewing and mixing food with saliva.
- Forms a bolus for swallowing.
- Helps in speech and articulation.
- Assists in oral cleaning.

Clinical Importance

- Glossitis: Inflammation of the tongue.
- Ankyloglossia: Restricted tongue movement due to a short or tight lingual frenulum.
- Oral candidiasis: Fungal infection that may affect the tongue.
- Tongue cancer: Malignant growth, commonly involving the squamous epithelium.
- Ageusia: Loss of taste.
- Dysgeusia: Distorted taste sensation.

6. Skin - Organ of Touch

Definition

The skin is the largest organ of the human body. It forms the external protective covering and contains sensory receptors for touch, pressure, pain and temperature.

Functions of the Skin

- Protects the body from injury and microorganisms.
- Prevents excessive water loss.
- Regulates body temperature.
- Provides sensory information.
- Helps in vitamin D synthesis.
- Excretes small amounts of water and salts through sweat.
- Provides immune defence.

Nurses Content
Downloaded from nursescontent.com

Layers of the Skin

The skin consists of two main layers:

A. Epidermis

- Outermost layer of the skin.
- Made of keratinised stratified squamous epithelium.
- Contains no blood vessels.
- Receives nutrients by diffusion from the dermis.

Layers of the Epidermis

From deep to superficial:

1. Stratum basale - deepest layer; produces new keratinocytes.
2. Stratum spinosum - provides strength and structural support.
3. Stratum granulosum - involved in keratinisation.
4. Stratum lucidum - present mainly in thick skin, such as palms and soles.
5. Stratum corneum - outermost layer of dead, keratinised cells.

B. Dermis

- Located below the epidermis.
- Made of connective tissue.
- Contains blood vessels, nerves, sensory receptors, hair follicles and glands.

It has two layers:

1. Papillary Layer
   - Superficial layer.
   - Made of loose connective tissue.
   - Contains dermal papillae and capillary loops.
2. Reticular Layer
   - Deeper and thicker layer.
   - Made mainly of dense irregular connective tissue.
   - Provides strength and elasticity.

C. Hypodermis (Subcutaneous Tissue)

The hypodermis lies beneath the skin but is not technically part of the skin itself.

It contains loose connective tissue and adipose tissue.

Functions:

- Provides insulation.
- Stores fat.

- Cushions underlying structures.
- Allows the skin to move over deeper tissues.

Skin Appendages

1. Hair

- Protects the skin.
- Helps detect light touch.
- Provides insulation in certain body regions.

2. Nails

- Protect the tips of fingers and toes.
- Help with grasping and fine movements.
- Support tactile functions.

3. Sweat Glands

Two main types:

Eccrine Sweat Glands

- Distributed over most of the body.
- Produce watery sweat.
- Important for temperature regulation.

Apocrine Sweat Glands

- Mainly found in the axillae, areolae and anogenital regions.
- Become active around puberty.
- Produce a thicker secretion into hair follicles in many locations.

4. Sebaceous Glands

- Usually associated with hair follicles.
- Produce sebum.
- Lubricate and protect the skin and hair.

Sensory Receptors of the Skin

Receptor

Main Function

Free nerve endings

Pain, temperature and crude touch

Merkel discs

Sustained light touch and texture

Nurses Content
Downloaded from nursescontent.com

Meissner corpuscles

Fine touch and low-frequency vibration

Pacinian corpuscles

Deep pressure and high-frequency vibration

Ruffini endings

Skin stretch and sustained pressure

Hair follicle receptors

Detect hair movement

Functions of the Skin in Detail

1. Protection: Acts as a barrier against microorganisms, chemicals, injury and water loss.

2. Temperature Regulation: Sweating and changes in skin blood flow help regulate body temperature.

3. Sensation: Receptors detect touch, pressure, vibration, pain and temperature.

4. Vitamin D Synthesis: Ultraviolet B radiation helps initiate vitamin D synthesis in the skin.

5. Excretion: Sweat removes small quantities of water, salts and other substances.

Clinical Importance

- Burns: Tissue damage caused by heat, chemicals, electricity or radiation.
- Dermatitis: Inflammation of the skin.
- Psoriasis: Chronic immune-mediated inflammatory skin disease.
- Acne vulgaris: Disorder involving pilosebaceous units.
- Pressure injuries: Localised damage to skin and underlying tissue, usually over bony prominences.
- Vitiligo: Loss of skin pigmentation due to melanocyte destruction or dysfunction.
- Skin cancer: Malignant growth arising from skin cells.

7. Comparison of the Five Sensory Organs

Organ

Sense

Main Receptor or Structure

Eye

Vision

Rods and cones in retina

Ear

Hearing and balance

Hair cells in cochlea and vestibular apparatus

Nose

Nurses Content
Downloaded from nursescontent.com

Smell

Olfactory receptor cells

Tongue

Taste

Taste receptor cells in taste buds

Skin

Touch and general sensation

Cutaneous sensory receptors

8. Nursing Importance of Sensory Organs

Knowledge of sensory organs is important in nursing assessment and patient care.

Nurses should:

- Assess visual acuity and observe for eye redness, discharge or visual changes.
- Assess hearing and identify difficulty understanding speech.
- Observe for ear pain, discharge and balance problems.
- Assess smell and identify changes in olfactory function when clinically relevant.
- Observe the tongue and oral cavity for ulcers, inflammation and abnormal colour.
- Assess skin colour, temperature, moisture, texture and integrity.
- Monitor for pressure injuries, burns and skin infections.
- Provide eye, ear, oral and skin hygiene.
- Educate patients about sensory protection and injury prevention.
- Report sudden vision loss, sudden hearing loss or acute neurological changes promptly.

9. Important Examination Questions

Long Answer Questions

1. Describe the structure of the human eye with a labelled diagram.
2. Explain the structure and functions of the three parts of the ear.
3. Describe the anatomy and functions of the skin.
4. Explain the structure and functions of the tongue.
5. Describe the anatomy of the nose and its role in olfaction.

Short Answer Questions

1. Write the layers of the eyeball.
2. Differentiate between rods and cones.
3. Name the three auditory ossicles.

Nurses Content
Downloaded from nursescontent.com

4. Write the functions of the semicircular canals.
5. Name the paranasal sinuses.
6. Describe the types of papillae of the tongue.
7. Write the layers of the epidermis.
8. Differentiate between epidermis and dermis.
9. Name the sensory receptors of the skin.
10. Write the functions of the lacrimal apparatus.

Very Short Answer Questions

1. Which organ is responsible for vision? - Eye.
2. Which nerve carries visual information? - Optic nerve (II).
3. Which is the smallest bone in the human body? - Stapes.
4. Which structure controls the amount of light entering the eye? - Iris.
5. Which part of the ear is responsible for hearing? - Cochlea.
6. Which nerve is responsible for smell? - Olfactory nerve (I).
7. Which structure contains taste buds? - Mainly fungiform, foliate and circumvallate papillae.
8. What is the largest organ of the body? - Skin.
9. Which layer of the skin contains blood vessels? - Dermis.
10. Which skin receptors detect deep pressure and vibration? - Pacinian corpuscles.

10. Quick Revision

- Eye is the organ of vision.
- Retina contains rods and cones.
- Cornea provides most of the eye's refractive power.
- Iris controls pupil size.
- Lens focuses light onto the retina.
- Ear is responsible for hearing and balance.
- The three auditory ossicles are malleus, incus and stapes.
- Cochlea is responsible for hearing.
- Semicircular canals detect rotational movements.
- Nose is the primary organ of smell.
- Olfactory nerve is cranial nerve I.
- Tongue is responsible for taste and assists in speech and swallowing.
- The five basic taste sensations are sweet, salty, sour, bitter and umami.
- Skin is the largest organ of the body.

Nurses Content
Downloaded from nursescontent.com

- Epidermis is the outer layer of skin.
- Dermis contains blood vessels, nerves and skin appendages.
- Pacinian corpuscles detect deep pressure and vibration.
- Eccrine sweat glands help regulate body temperature.

Conclusion

Sensory organs help the body detect and interpret information from the environment. The eye, ear, nose, tongue and skin perform specialised functions related to vision, hearing, balance, smell, taste and touch. Understanding their anatomy is essential for nursing students to assess sensory function, recognise abnormalities and provide appropriate patient care.

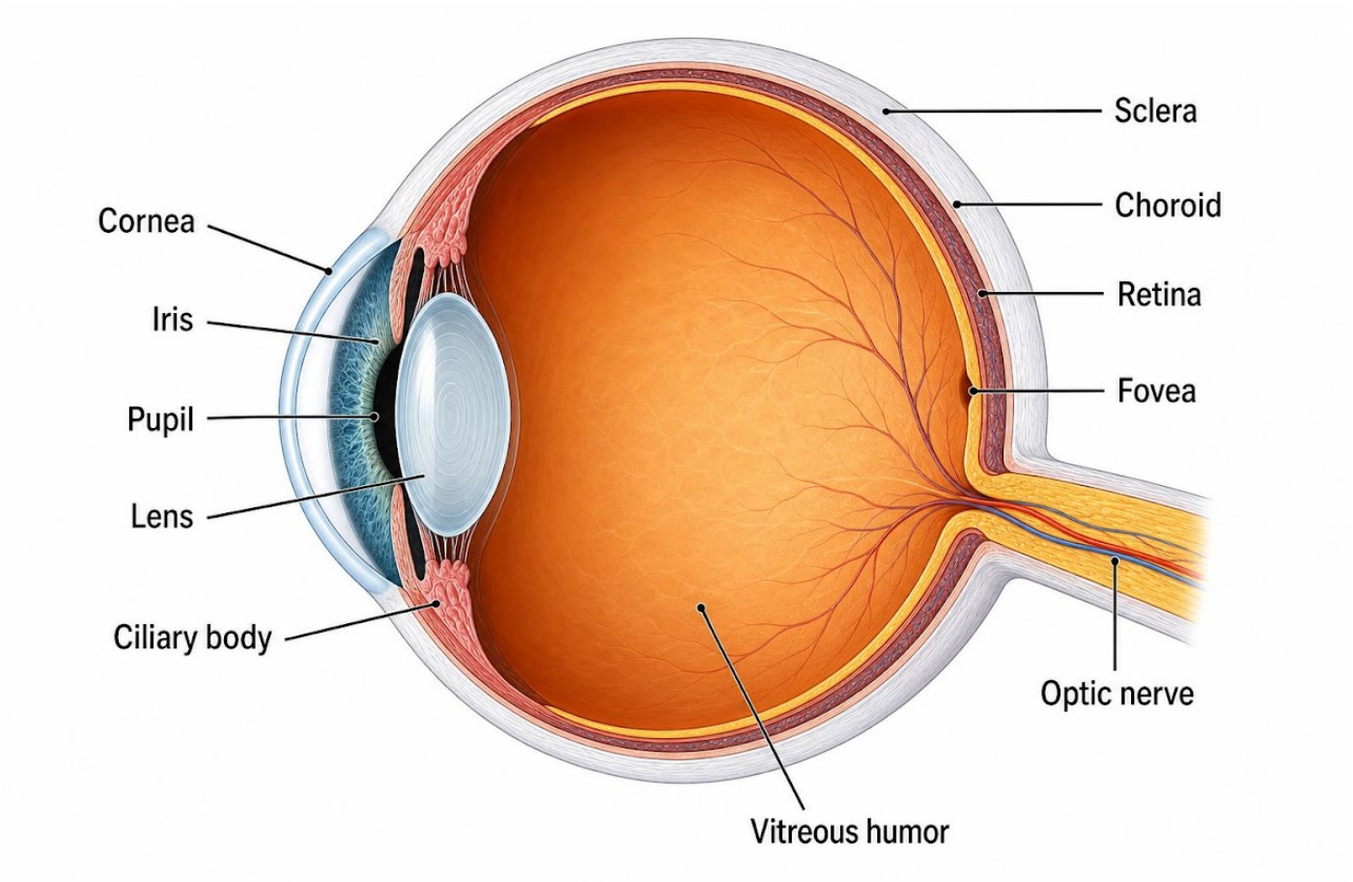

Sensory Organs - illustration 1

Nurses Content
Downloaded from nursescontent.com

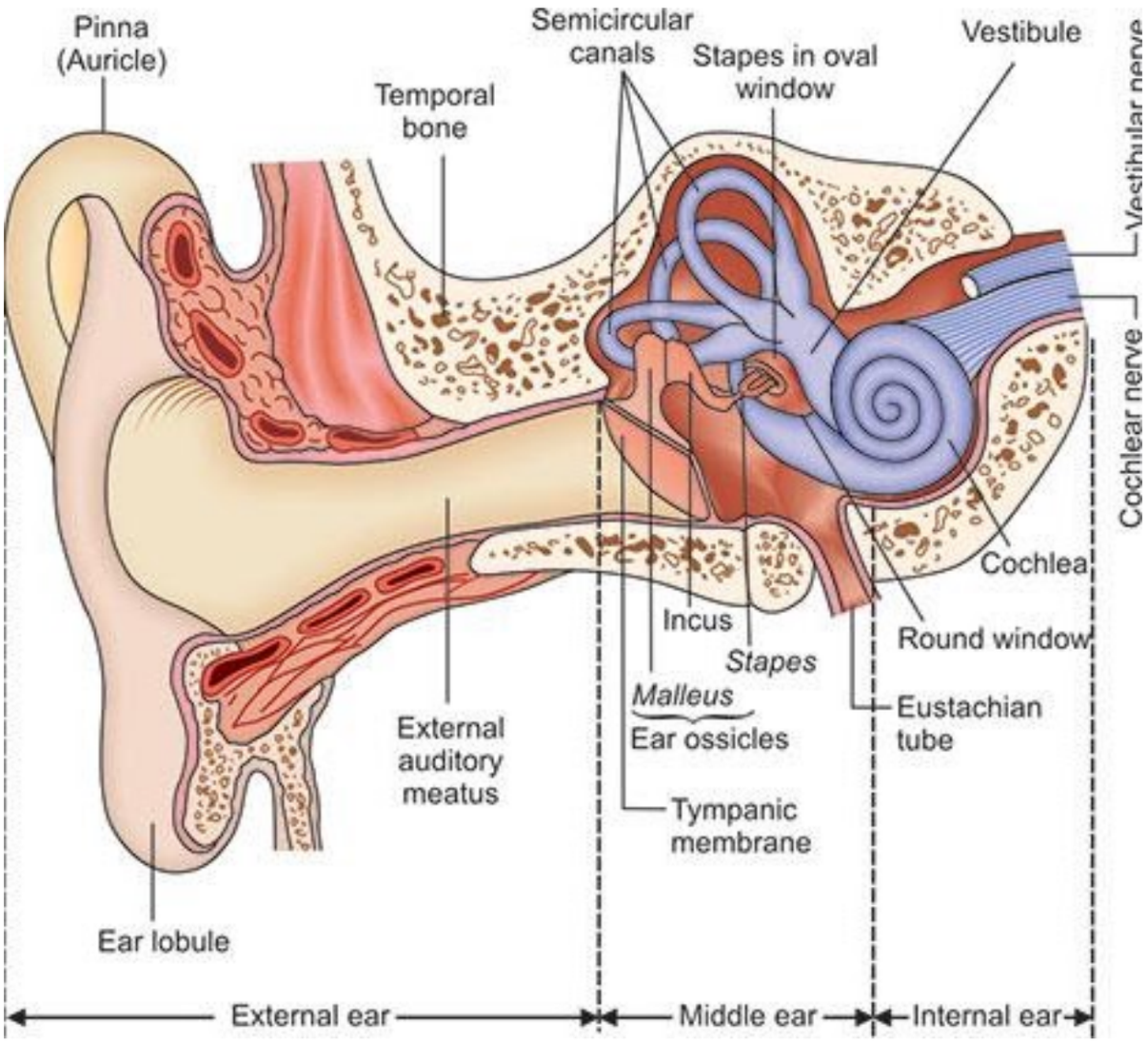

Sensory Organs - illustration 2

Nurses Content
Downloaded from nursescontent.com

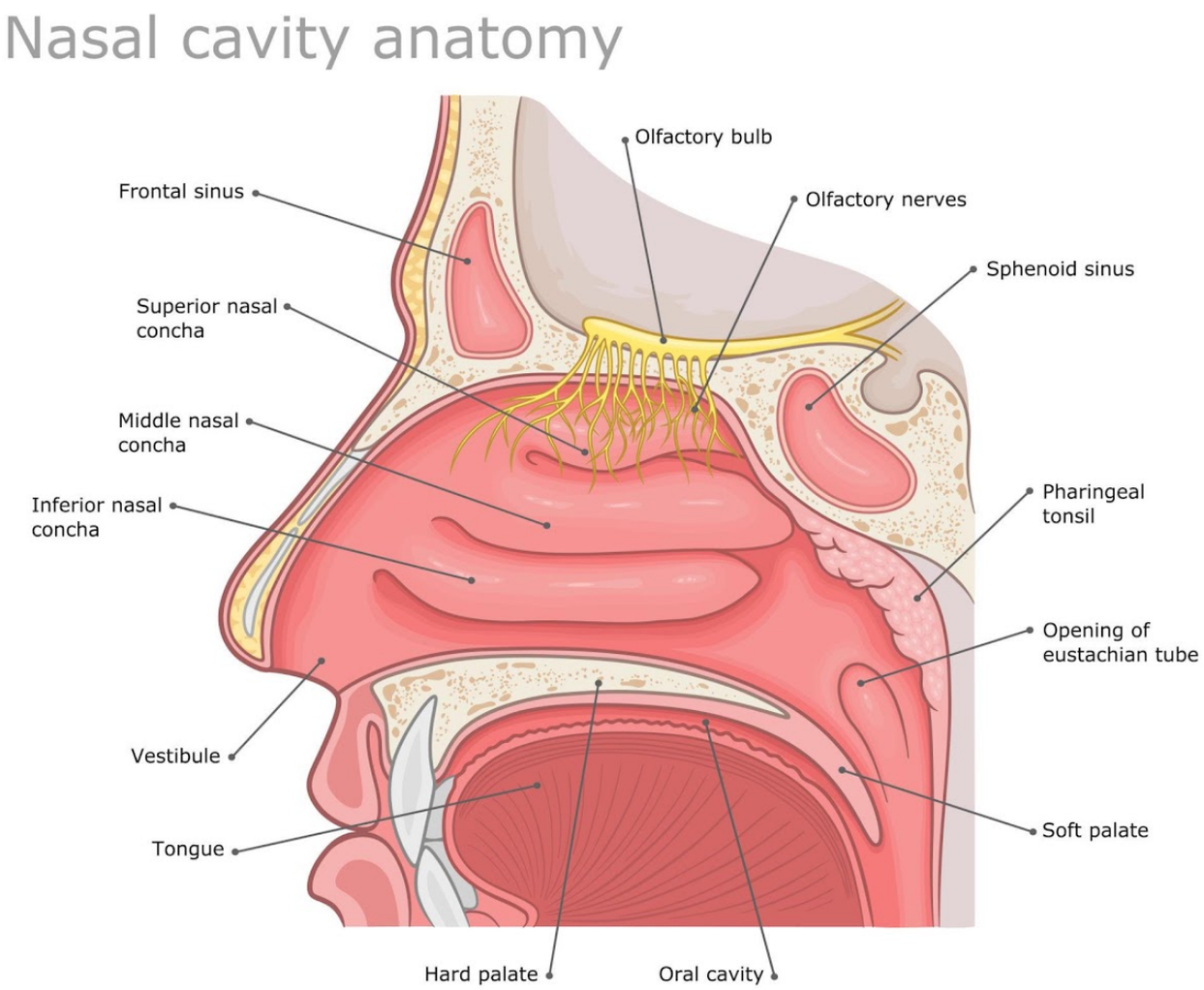

Sensory Organs - illustration 3

Nurses Content
Downloaded from nursescontent.com

Specialized Mucosa – Dorsal Tongue

Types of papilla: 4 types

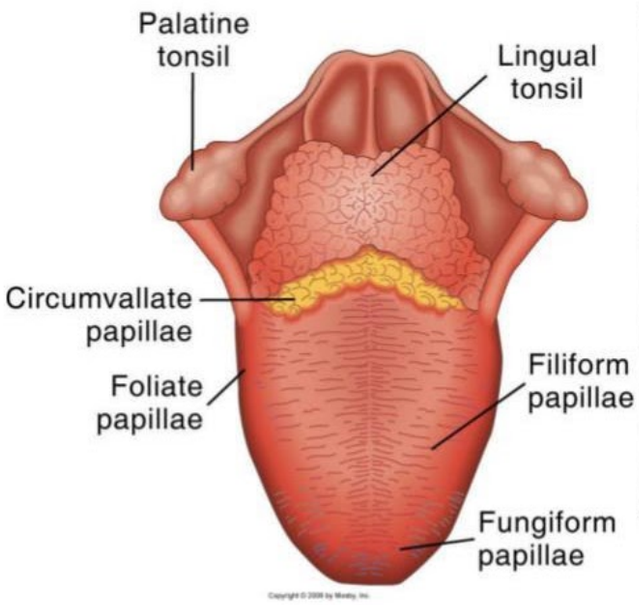

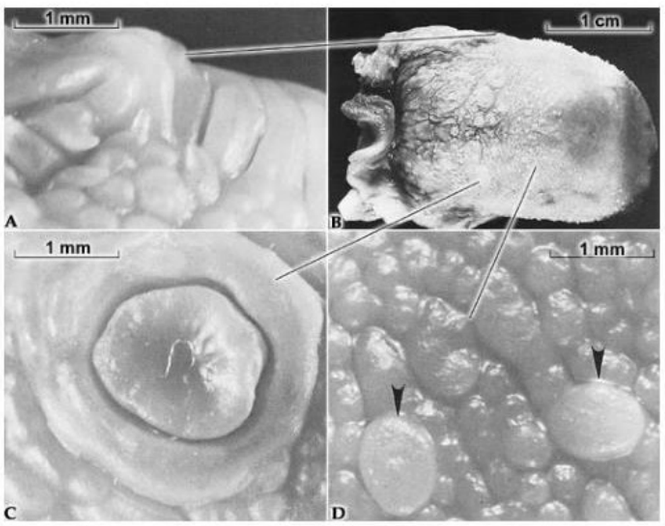

A: Foliate
C: Circumvallate
D: Filiform

45

Sensory Organs - illustration 4

Nurses Content
Downloaded from nursescontent.com

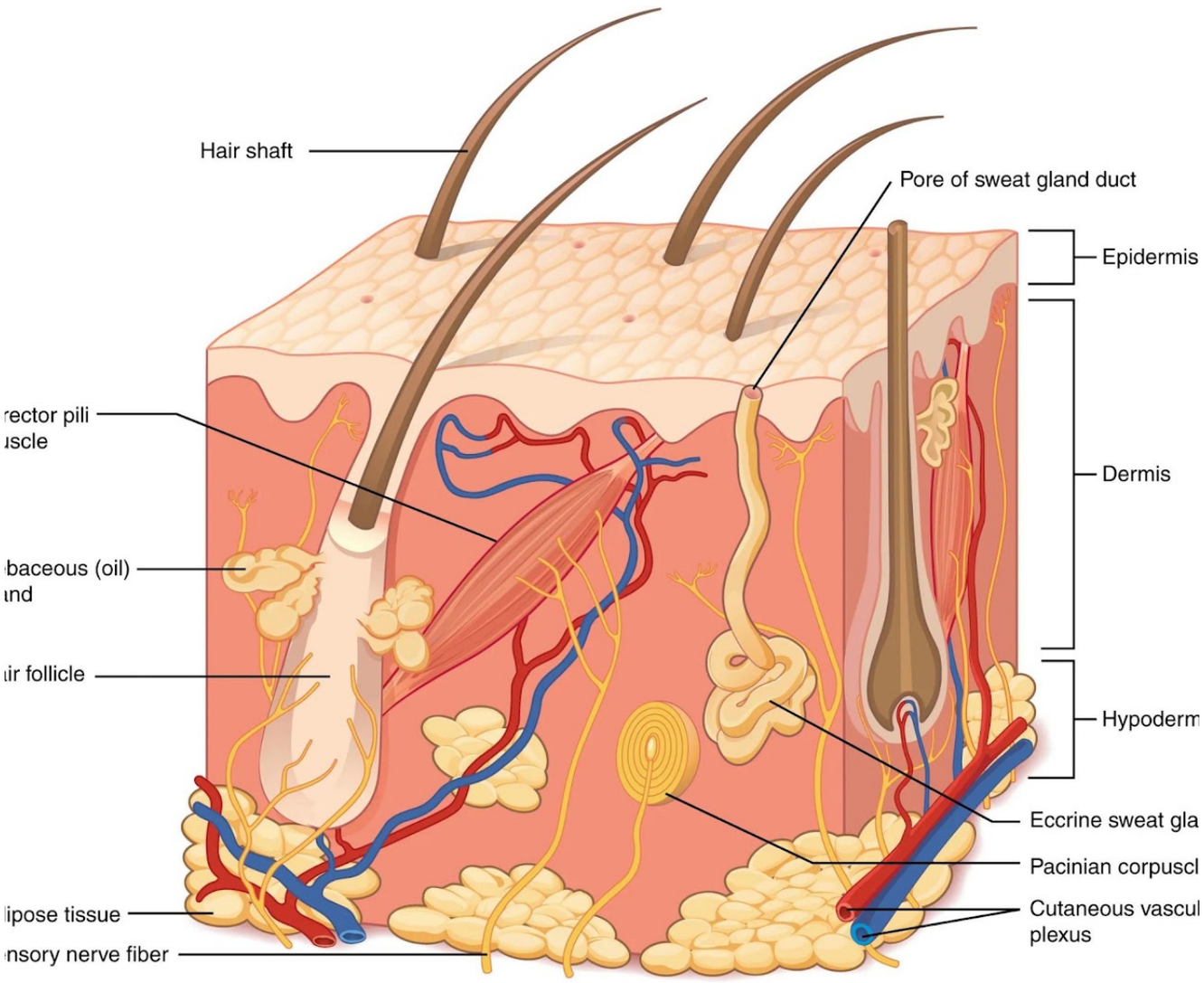

Sensory Organs - illustration 5

Nurses Content
Downloaded from nursescontent.com

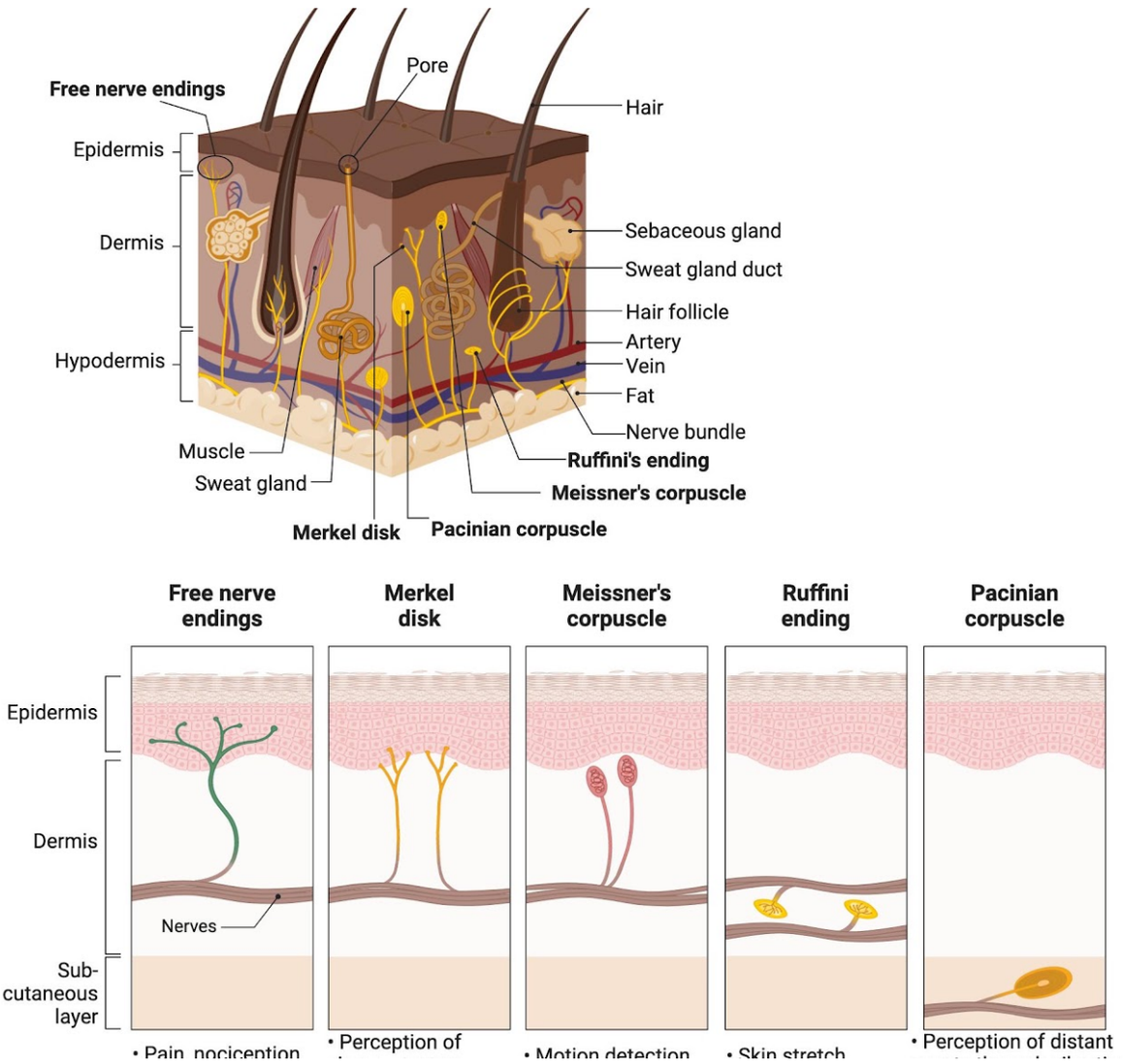

Sensory Organs - illustration 6

Quick Revision

- Eye: The eyeball has a fibrous coat (sclera and cornea), vascular coat (choroid, ciliary body and iris) and neural coat (retina). The lens lies behind the iris. Aqueous humour occupies anterior segment chambers; vitreous fills the posterior cavity.

- Ear: The tympanic membrane separates the external canal from the middle ear. The cochlea supports hearing; the vestibular apparatus supports balance.

- Nose & tongue: Olfactory epithelium lies high in the nasal cavity and connects through cranial nerve I. Taste buds occur in several tongue papillae; filiform papillae mainly serve mechanical functions and lack taste buds. Taste quality is not restricted to separate tongue-map zones.

- Skin: Skin consists of epidermis and dermis; hypodermis lies beneath. The avascular epidermis is keratinized stratified squamous epithelium. The dermis contains vessels, nerves, follicles and glands. Thick skin on palms and soles has a stratum lucidum and no hair follicles.

Examination questions

1. List three coats of the eye.

2. Name the middle-ear ossicles in order.

Nurses Content
Downloaded from nursescontent.com

3. Compare epidermis and dermis.

Practice questions

Choose one best answer. The answer key and explanations follow the questions.

1. Which layer of the skin is avascular?

A. Dermis
B. Epidermis
C. Hypodermis
D. All layers

2. Which ossicle contacts the oval window?

A. Malleus
B. Incus
C. Stapes
D. Cochlea

3. Which papillae lack taste buds?

A. Filiform
B. Fungiform
C. Circumvallate
D. Foliate

Nurses Content
Downloaded from nursescontent.com

Answer key and explanations

1. B - Epidermis

The epidermis receives nutrients by diffusion from underlying tissue.

2. C - Stapes

The stapes footplate transmits vibration at the oval window.

3. A - Filiform

Filiform papillae provide a mechanical surface.

Source and attribution

Online chapter: https://nursescontent.com/learn/anatomy-physiology/sensory-organs/

Downloaded from Nurses Content. Branding identifies the delivery website. Original author credits, third-party licences and applicable rights remain unchanged.