Nurses Content
Downloaded from nursescontent.com

Nervous System

Anatomy & Physiology

Brain, spinal cord, nerves and autonomic nervous system

For educational purposes only.

Nervous System - B.Sc. Nursing Applied Anatomy Notes

1. Introduction

The nervous system is the body's main communication and control system. It receives sensory information, processes it and coordinates appropriate responses.

It controls voluntary movements, involuntary activities, sensation, memory, thinking and emotions.

2. Divisions of the Nervous System

The nervous system is divided into two main parts:

A. Central Nervous System (CNS)

Consists of:

1. Brain
2. Spinal cord

Functions:

- Receives and processes information.
- Controls body activities.
- Coordinates movement and reflexes.
- Regulates vital functions.

B. Peripheral Nervous System (PNS)

Consists of:

- Cranial nerves
- Spinal nerves
- Peripheral ganglia and nerve endings

Functions:

- Connects the CNS with the rest of the body.
- Carries sensory information to the CNS.
- Carries motor commands from the CNS to muscles and glands.

Functional Divisions

1. Sensory (afferent) division: Carries impulses from receptors toward the CNS.

Nurses Content
Downloaded from nursescontent.com

2. Motor (efferent) division: Carries impulses from the CNS to effectors.

The motor division is further divided into:

- Somatic nervous system: Mainly controls voluntary skeletal muscle activity.
- Autonomic nervous system: Regulates involuntary functions of smooth muscle, cardiac muscle and glands.

3. Neuron

Definition

A neuron is the structural and functional unit of the nervous system. It is a specialised cell that receives and transmits nerve impulses.

Structure of Neuron

A typical neuron consists of three main parts:

1. Cell Body (Soma)

- Contains the nucleus.
- Contains cytoplasm and cell organelles.
- Controls the metabolic activities of the neuron.

2. Dendrites

- Short, branched extensions.
- Receive signals from other neurons or receptors.
- Carry signals toward the cell body.

3. Axon

- A long extension that carries nerve impulses away from the cell body.
- May be covered by a myelin sheath.
- Ends in terminal branches that communicate with other cells.

Myelin Sheath

The myelin sheath is a fatty insulating covering around many axons.

Functions:

- Protects and insulates the axon.
- Increases the speed of nerve impulse conduction.
- Supports saltatory conduction between nodes of Ranvier.

In the CNS, myelin is produced by oligodendrocytes. In the PNS, it is produced by Schwann cells.

Types of Neurons

Type

Function

Nurses Content
Downloaded from nursescontent.com

Sensory neurons

Carry impulses from receptors to the CNS

Motor neurons

Carry impulses from the CNS to effectors

Interneurons

Connect neurons within the CNS

Neuroglia (Glial Cells)

Neuroglia are supporting cells of the nervous system.

Cell

Main function

Astrocytes

Support neurons and help maintain the blood-brain barrier

Oligodendrocytes

Form myelin in the CNS

Microglia

Immune defence and removal of cellular debris

Ependymal cells

Line the ventricles and central canal

Schwann cells

Form myelin in the PNS

Satellite cells

Support neuron cell bodies in peripheral ganglia

Synapse

A synapse is a functional junction through which one neuron communicates with another neuron or an effector cell.

Types:

- Chemical synapse
- Electrical synapse

At a chemical synapse, neurotransmitters carry signals across the synaptic cleft.

Examples of neurotransmitters:

- Acetylcholine
- Dopamine
- Serotonin

- Noradrenaline
- GABA
- Glutamate

4. Brain

Definition

The brain is the main control centre of the nervous system. It is located inside the cranial cavity and is protected by the skull, meninges and cerebrospinal fluid.

Location and Weight

- Located within the cranial cavity.
- Average adult weight is approximately 1.3-1.4 kg, with individual variation.

Protection of the Brain

The brain is protected by:

1. Skull (cranium)
2. Meninges
3. Cerebrospinal fluid (CSF)
4. Blood-brain barrier

Meninges

The meninges are three protective membranes surrounding the brain and spinal cord.

1. Dura Mater

- Outermost and toughest membrane.
- Provides mechanical protection.
- Forms dural venous sinuses in the cranial cavity.

2. Arachnoid Mater

- Middle, thin membrane.
- Lies beneath the dura mater.
- The subarachnoid space beneath it contains CSF and blood vessels.

3. Pia Mater

- Innermost delicate membrane.
- Closely follows the surface of the brain and spinal cord.
- Contains blood vessels.

Nurses Content
Downloaded from nursescontent.com

Major Divisions of the Brain

The brain is divided into:

1. Cerebrum
2. Diencephalon
3. Brainstem
4. Cerebellum

A. Cerebrum

The cerebrum is the largest part of the brain.

Structure

- Divided into right and left cerebral hemispheres.
- The hemispheres are connected mainly by the corpus callosum.
- The outer layer is the cerebral cortex, made of grey matter.
- The inner region contains white matter.
- The surface has folds called gyri and grooves called sulci.

Lobes of Cerebrum

Each cerebral hemisphere has five commonly described lobes:

1. Frontal Lobe

Functions:

- Voluntary movement.
- Planning and decision-making.
- Personality and behaviour.
- Speech production through Broca's area in the dominant hemisphere.

2. Parietal Lobe

Functions:

- Processes touch, pressure, pain and temperature.
- Helps with spatial awareness.
- Integrates sensory information.

3. Temporal Lobe

Functions:

- Hearing.
- Memory.
- Language comprehension through Wernicke's area in the dominant hemisphere.
- Recognition of sounds and objects.

Nurses Content
Downloaded from nursescontent.com

4. Occipital Lobe

Functions:

- Main centre for visual processing.

5. Insula

Functions:

- Taste processing.
- Visceral sensation.
- Integration of emotional and bodily information.

Functional Areas of Cerebrum

Area

Function

Motor area

Controls voluntary movements

Sensory area

Receives body sensations

Visual area

Processes vision

Auditory area

Processes hearing

Broca's area

Speech production

Wernicke's area

Language comprehension

B. Diencephalon

The diencephalon is located between the cerebrum and brainstem.

Main structures:

1. Thalamus

- Major relay centre for most sensory information going to the cerebral cortex.
- Plays a role in alertness and awareness.

2. Hypothalamus

- Regulates body temperature.
- Controls hunger and thirst.
- Helps regulate sleep and circadian rhythms.

Nurses Content
Downloaded from nursescontent.com

- Controls autonomic functions.
- Regulates pituitary hormone secretion.
- Helps maintain homeostasis.

3. Epithalamus

- Includes the pineal gland.
- Pineal gland secretes melatonin, which helps regulate the sleep-wake cycle.

C. Brainstem

The brainstem connects the brain with the spinal cord.

It consists of three parts:

1. Midbrain

Functions:

- Controls visual and auditory reflexes.
- Helps regulate eye movements.
- Contains pathways connecting different parts of the nervous system.

2. Pons

Functions:

- Connects different parts of the brain.
- Participates in respiratory regulation.
- Contains pathways and cranial nerve nuclei.

3. Medulla Oblongata

Functions:

- Regulates heart rate.
- Helps control blood pressure.
- Controls respiratory activity.
- Contains reflex centres for swallowing, coughing, sneezing and vomiting.

D. Cerebellum

The cerebellum is located behind the brainstem and below the occipital lobes.

Functions

- Coordinates voluntary movements.
- Maintains posture and balance.
- Regulates muscle tone.
- Helps in motor learning.

- Coordinates precision and timing of movements.

5. Ventricles of the Brain and Cerebrospinal Fluid

Ventricles of Brain

The ventricles are interconnected cavities within the brain containing cerebrospinal fluid.

There are four main ventricles:

1. Two lateral ventricles.
2. Third ventricle.
3. Fourth ventricle.

The lateral ventricles communicate with the third ventricle through the interventricular foramina. The third and fourth ventricles are connected by the cerebral aqueduct.

Cerebrospinal Fluid (CSF)

Definition

CSF is a clear, colourless fluid that surrounds the brain and spinal cord and fills the ventricles.

Formation

- Mainly produced by the choroid plexuses within the ventricles.
- Circulates through the ventricular system and subarachnoid space.
- Reabsorbed mainly through arachnoid granulations into dural venous sinuses.

Functions

- Protects the CNS from mechanical injury.
- Provides buoyancy to the brain.
- Helps maintain a stable chemical environment.
- Transports nutrients and removes waste products.

Approximate adult CSF volume: 150 mL.

6. Spinal Cord

Definition

The spinal cord is a long, cylindrical structure of nervous tissue that extends from the medulla oblongata through the vertebral canal.

Location and Extent

- Lies within the vertebral canal.
- Begins at the foramen magnum as a continuation of the medulla oblongata.
- In adults, usually ends at the level of the L1-L2 vertebrae as the conus medullaris.

Nurses Content
Downloaded from nursescontent.com

Enlargements of Spinal Cord

Two major enlargements are present:

1. Cervical enlargement: Supplies nerves to the upper limbs.
2. Lumbosacral enlargement: Supplies nerves to the lower limbs.

Lower End Structures

- Conus medullaris: Tapered lower end of the spinal cord.
- Cauda equina: Bundle of lumbar, sacral and coccygeal nerve roots below the conus medullaris.
- Filum terminale: Fibrous extension that helps anchor the spinal cord.

Internal Structure of Spinal Cord

The spinal cord contains:

Grey Matter

- Located centrally.
- Appears H-shaped or butterfly-shaped.
- Contains neuron cell bodies and synapses.

Its main horns are:

- Anterior (ventral) horns: Contain motor neuron cell bodies.
- Posterior (dorsal) horns: Receive sensory information.
- Lateral horns: Contain autonomic neurons at certain spinal levels.

White Matter

- Located around the grey matter.
- Contains myelinated nerve fibres.
- Forms ascending and descending tracts.

Functions of Spinal Cord

- Conducts sensory impulses to the brain.
- Carries motor impulses from the brain.
- Acts as a reflex centre.
- Helps coordinate certain automatic responses.

7. Spinal Nerves

Definition

Spinal nerves are mixed peripheral nerves formed by the union of anterior and posterior roots of the spinal cord.

Nurses Content
Downloaded from nursescontent.com

Number of Spinal Nerves

There are 31 pairs of spinal nerves:

Region

Number of pairs

Cervical

8

Thoracic

12

Lumbar

5

Sacral

5

Coccygeal

1

Total

31

Formation of Spinal Nerve

Each spinal nerve is formed by:

1. Posterior (dorsal) root: Carries sensory impulses toward the spinal cord and contains a dorsal root ganglion.
2. Anterior (ventral) root: Carries motor impulses away from the spinal cord.

The two roots unite to form a mixed spinal nerve.

Functions

- Carry sensory information from the body.
- Carry motor commands to muscles.
- Carry autonomic fibres to organs and tissues.

Major Nerve Plexuses

A nerve plexus is a network formed by the anterior rami of spinal nerves.

1. Cervical Plexus

- Formed mainly by C1-C4.
- Supplies parts of the neck.
- Gives rise to the phrenic nerve (C3-C5), which supplies the diaphragm.

Nurses Content
Downloaded from nursescontent.com

2. Brachial Plexus

- Formed by C5-T1.
- Supplies the shoulder and upper limb.
- Major nerves include:Musculocutaneous nerveAxillary nerveRadial nerveMedian nerveUlnar nerve

3. Lumbar Plexus

- Formed mainly by L1-L4.
- Supplies parts of the lower abdominal wall and anterior and medial thigh.
- Major nerves include femoral and obturator nerves.

4. Sacral Plexus

- Formed mainly by L4-S4.
- Supplies the pelvis, buttocks and much of the lower limb.
- Gives rise to the sciatic nerve, the largest nerve in the body.

8. Cranial Nerves

Definition

Cranial nerves are nerves that arise directly from the brain or brainstem and mainly supply structures of the head and neck, with the vagus nerve also supplying thoracic and abdominal organs.

There are 12 pairs of cranial nerves.

No.

Cranial nerve

Main function

I

Olfactory

Smell

II

Optic

Vision

III

Oculomotor

Most eye movements, eyelid elevation and pupil constriction

IV

Trochlear

Supplies superior oblique muscle of eye

V

Nurses Content
Downloaded from nursescontent.com

Trigeminal

Facial sensation and muscles of mastication

VI

Abducens

Supplies lateral rectus muscle

VII

Facial

Facial expression, taste from anterior two-thirds of tongue and some glandular secretion

VIII

Vestibulocochlear

Hearing and balance

IX

Glossopharyngeal

Taste and sensation from posterior one-third of tongue; swallowing functions

X

Vagus

Autonomic supply to many thoracic and abdominal organs; swallowing and voice functions

XI

Accessory

Supplies sternocleidomastoid and trapezius muscles

XII

Hypoglossal

Tongue movements

Classification of Cranial Nerves

Sensory Nerves

- I - Olfactory
- II - Optic
- VIII - Vestibulocochlear

Motor Nerves

- III - Oculomotor
- IV - Trochlear
- VI - Abducens
- XI - Accessory

Nurses Content
Downloaded from nursescontent.com

- XII - Hypoglossal

Mixed Nerves

- V - Trigeminal
- VII - Facial
- IX - Glossopharyngeal
- X - Vagus

9. Autonomic Nervous System (ANS)

Definition

The autonomic nervous system is the part of the peripheral nervous system that regulates involuntary functions of smooth muscle, cardiac muscle and glands.

It helps maintain homeostasis.

Divisions of Autonomic Nervous System

1. Sympathetic nervous system.
2. Parasympathetic nervous system.
3. Enteric nervous system.

A. Sympathetic Nervous System

Definition

The sympathetic nervous system prepares the body for stressful situations and is commonly described as the "fight or flight" system.

Origin

- Thoracolumbar outflow.
- Arises from spinal cord segments T1-L2.

Functions

- Increases heart rate and force of contraction.
- Dilates pupils.
- Dilates bronchi.
- Reduces gastrointestinal motility and secretion.
- Promotes sweating.
- Stimulates glucose release.
- Relaxes the bladder detrusor during storage.
- Promotes ejaculation.

Nurses Content
Downloaded from nursescontent.com

B. Parasympathetic Nervous System

Definition

The parasympathetic nervous system supports resting activities, digestion and energy conservation. It is commonly called the "rest and digest" system.

Origin

- Craniosacral outflow.
- Arises from cranial nerves III, VII, IX and X and sacral spinal segments S2-S4.

Functions

- Decreases heart rate.
- Constricts pupils.
- Constricts bronchi in appropriate conditions.
- Increases gastrointestinal motility and secretion.
- Promotes digestion.
- Contracts the bladder detrusor during urination.
- Supports erection.

C. Enteric Nervous System

- Located in the wall of the gastrointestinal tract.
- Contains the myenteric and submucosal plexuses.
- Regulates intestinal movement and secretion.
- Can function independently but is influenced by sympathetic and parasympathetic systems.

Difference Between Sympathetic and Parasympathetic Systems

Feature

Sympathetic

Parasympathetic

Main role

Fight or flight

Rest and digest

Origin

T1-L2

Craniosacral

Heart rate

Increases

Nurses Content
Downloaded from nursescontent.com

Decreases

Pupil

Dilates

Constricts

Bronchi

Dilates

Constricts

Digestion

Generally decreases activity

Generally increases activity

Bladder

Supports urine storage

Promotes urination

Salivation

Usually reduces watery secretion

Increases watery secretion

Autonomic Neurotransmitters

- Acetylcholine: Released by all autonomic preganglionic neurons and most parasympathetic postganglionic neurons.
- Noradrenaline: Released by most sympathetic postganglionic neurons.
- Adrenaline: Released mainly by the adrenal medulla into the bloodstream.

10. Reflex Action and Reflex Arc

Reflex Action

A reflex action is a rapid, automatic and involuntary response to a stimulus.

Examples:

- Withdrawal of hand from a hot object.
- Knee-jerk reflex.
- Blinking of eyes.
- Pupil constriction in response to light.

Reflex Arc

A reflex arc is the pathway followed by nerve impulses during a reflex action.

Nurses Content
Downloaded from nursescontent.com

Components

1. Receptor: Detects the stimulus.
2. Sensory neuron: Carries impulses toward the CNS.
3. Integration centre: Processes the information in the spinal cord or brainstem.
4. Motor neuron: Carries the response signal.
5. Effector: Muscle or gland that produces the response.

Importance: Reflexes protect the body and help maintain posture and normal function.

11. Blood Supply of the Brain and Spinal Cord

Blood Supply of Brain

The brain receives blood mainly through two paired arterial systems:

1. Internal carotid arteries.
2. Vertebral arteries.

The vertebral arteries join to form the basilar artery. Branches of the internal carotid and vertebrobasilar systems contribute to the Circle of Willis.

Importance

- Supplies oxygen and glucose to brain tissue.
- Maintains normal neuronal function.
- Interruption of blood flow can cause a stroke.

Blood Supply of Spinal Cord

The spinal cord is supplied by:

- One anterior spinal artery.
- Two posterior spinal arteries.
- Additional segmental and radicular arteries.

These vessels maintain blood flow to the spinal cord.

12. Common Disorders of the Nervous System

Disorder

Description

Stroke

Brain injury caused by interrupted blood supply or bleeding

Epilepsy

Disorder characterised by a tendency to recurrent unprovoked seizures

Meningitis

Inflammation of the meninges

Encephalitis

Inflammation of brain tissue

Parkinson's disease

Progressive neurological disorder affecting movement

Alzheimer's disease

Progressive neurodegenerative disorder affecting memory and cognition

Multiple sclerosis

Immune-mediated disease causing damage to CNS myelin

Cerebral palsy

Group of permanent disorders affecting movement and posture due to early brain injury or abnormal development

Spinal cord injury

Damage to the spinal cord causing sensory, motor or autonomic impairment

Peripheral neuropathy

Damage or dysfunction of peripheral nerves

Bell's palsy

Acute weakness or paralysis of facial muscles due to facial nerve dysfunction

Sciatica

Pain associated with irritation or compression of sciatic nerve roots or the sciatic nerve

13. Nursing Importance of the Nervous System

Knowledge of the nervous system is essential for neurological assessment, emergency care and monitoring patients with neurological disorders.

Neurological Assessment

Nurses should assess:

- Level of consciousness.
- Orientation to person, place and time.
- Pupil size, equality and reaction to light.
- Motor strength and limb movement.
- Sensory response.
- Speech and language.
- Balance and coordination.
- Vital signs.
- Presence of seizures or abnormal movements.

Nurses Content
Downloaded from nursescontent.com

Glasgow Coma Scale (GCS)

The Glasgow Coma Scale is used to assess a patient's level of consciousness.

It includes three components:

Component

Score

Eye opening (E)

1-4

Verbal response (V)

1-5

Motor response (M)

1-6

Total

3-15

- 15: Highest possible score.
- 3: Lowest possible score.
- A falling GCS requires prompt assessment and escalation.

Nursing Responsibilities

- Monitor neurological status regularly.
- Assess and document GCS when indicated.
- Maintain airway, breathing and circulation.
- Monitor vital signs and oxygen saturation.
- Implement seizure precautions for patients at risk.
- Maintain patient safety and prevent falls.
- Monitor for changes in pupil response and limb strength.
- Assist with positioning and mobility.
- Provide prescribed medications safely.
- Educate patients and caregivers about disease management and rehabilitation.

Important Emergency Warning Signs

Recognise the FAST signs of stroke:

- F - Face: Facial drooping.
- A - Arms: Weakness in one arm.
- S - Speech: Slurred or abnormal speech.
- T - Time: Seek emergency medical help immediately.

Nurses Content
Downloaded from nursescontent.com

Other warning signs include sudden severe headache, new seizures, sudden loss of vision, confusion or loss of consciousness.

14. Important Questions for Nursing Examinations

Long Answer Questions

1. Describe the structure and functions of the brain with a labelled diagram.
2. Explain the anatomy of the spinal cord.
3. Describe the divisions of the nervous system.
4. Explain the autonomic nervous system and its functions.
5. Describe the structure of a neuron with a labelled diagram.
6. Explain cranial nerves and their functions.
7. Describe the reflex arc with a diagram.

Short Answer Questions

1. Write the functions of the cerebrum.
2. Explain the functions of the cerebellum.
3. Write the three layers of meninges.
4. Describe the functions of CSF.
5. What are the ventricles of the brain?
6. Write the number of cranial and spinal nerves.
7. Explain the functions of the hypothalamus.
8. Differentiate between sympathetic and parasympathetic nervous systems.
9. What is a reflex action?
10. Write the functions of the spinal cord.

Very Short Answer Questions

1. What is the structural and functional unit of the nervous system? Answer: Neuron.
2. How many pairs of cranial nerves are present? Answer: 12 pairs.
3. How many pairs of spinal nerves are present? Answer: 31 pairs.
4. What is the largest part of the brain? Answer: Cerebrum.
5. Which part of the brain controls balance and coordination? Answer: Cerebellum.
6. Which part of the brain regulates breathing and heart rate? Answer: Medulla oblongata, along with other brainstem centres.
7. Which membrane is the outermost meninx? Answer: Dura mater.
8. Where is CSF mainly produced? Answer: Choroid plexuses.
9. Which nerve supplies the diaphragm? Answer: Phrenic nerve.

Nurses Content
Downloaded from nursescontent.com

10. Which spinal nerve roots carry sensory impulses? Answer: Posterior (dorsal) roots.
11. Which spinal nerve roots carry motor impulses? Answer: Anterior (ventral) roots.
12. What is the origin of the sympathetic nervous system? Answer: T1-L2 spinal cord segments.
13. What is the origin of the parasympathetic nervous system? Answer: Craniosacral outflow.
14. Which cranial nerve is responsible for smell? Answer: Olfactory nerve (I).
15. Which cranial nerve is responsible for vision? Answer: Optic nerve (II).

15. Quick Revision

- The nervous system is divided into CNS and PNS.
- CNS consists of the brain and spinal cord.
- PNS consists of cranial nerves, spinal nerves and ganglia.
- Neuron is the structural and functional unit.
- Dendrites receive signals; axons carry impulses away from the cell body.
- Myelin increases the speed of nerve conduction.
- The brain is protected by the skull, meninges and CSF.
- The meninges are dura mater, arachnoid mater and pia mater.
- The cerebrum controls higher functions and voluntary movement.
- The cerebellum coordinates movement and balance.
- The hypothalamus helps maintain homeostasis.
- The medulla regulates vital autonomic functions.
- The spinal cord is a major pathway for sensory and motor impulses.
- There are 12 pairs of cranial nerves.
- There are 31 pairs of spinal nerves.
- The sympathetic system is associated with fight or flight.
- The parasympathetic system is associated with rest and digest.
- Reflex action is a rapid, automatic response.
- CSF protects and supports the CNS.
- The Glasgow Coma Scale assesses eye, verbal and motor responses.

Conclusion

The nervous system coordinates and controls almost every activity of the human body. The brain and spinal cord form the central nervous system, while cranial and spinal nerves connect it with the rest of the body. The autonomic nervous system regulates involuntary functions and maintains homeostasis. Understanding nervous system anatomy is essential for neurological assessment, patient safety and nursing care.

Nurses Content
Downloaded from nursescontent.com

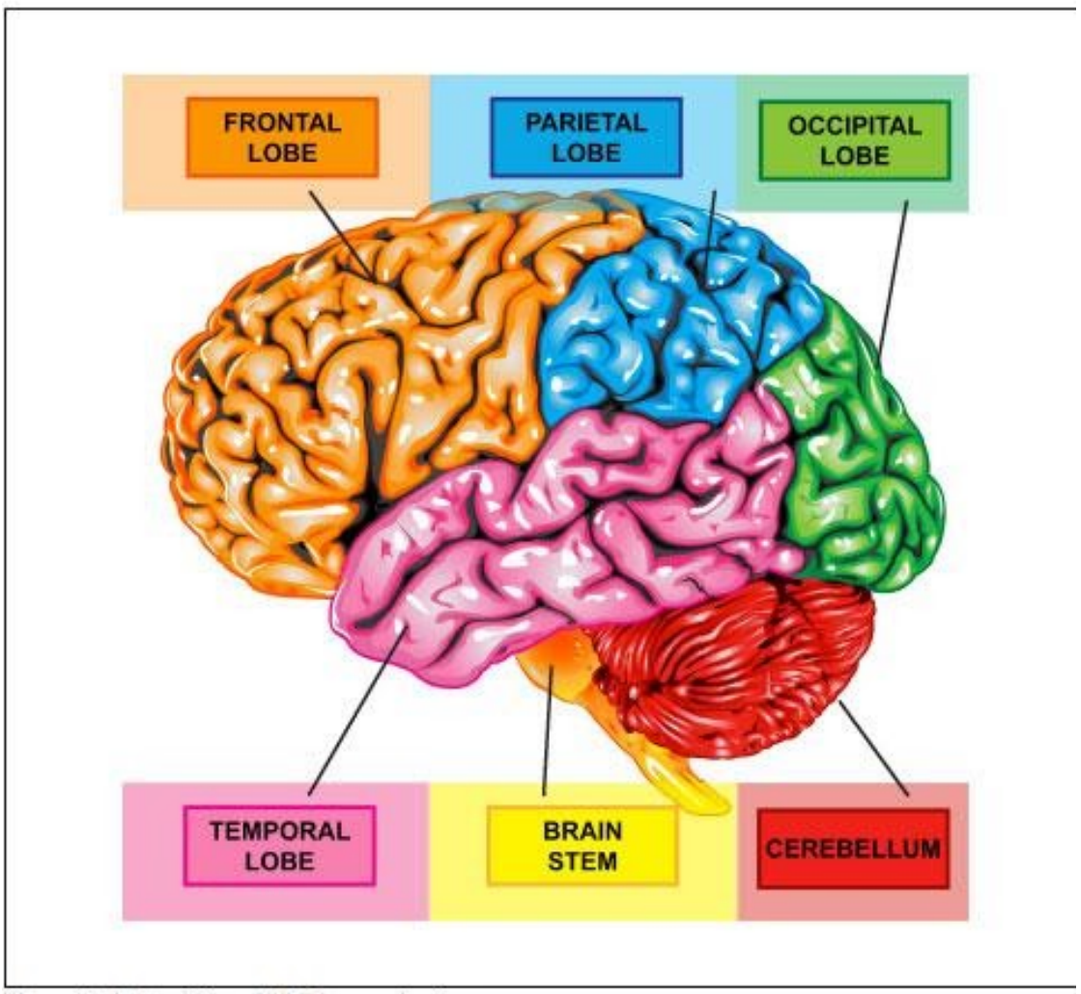

Figure 2. Lateral view of the human brain.

Nervous System - illustration 1

Nurses Content
Downloaded from nursescontent.com

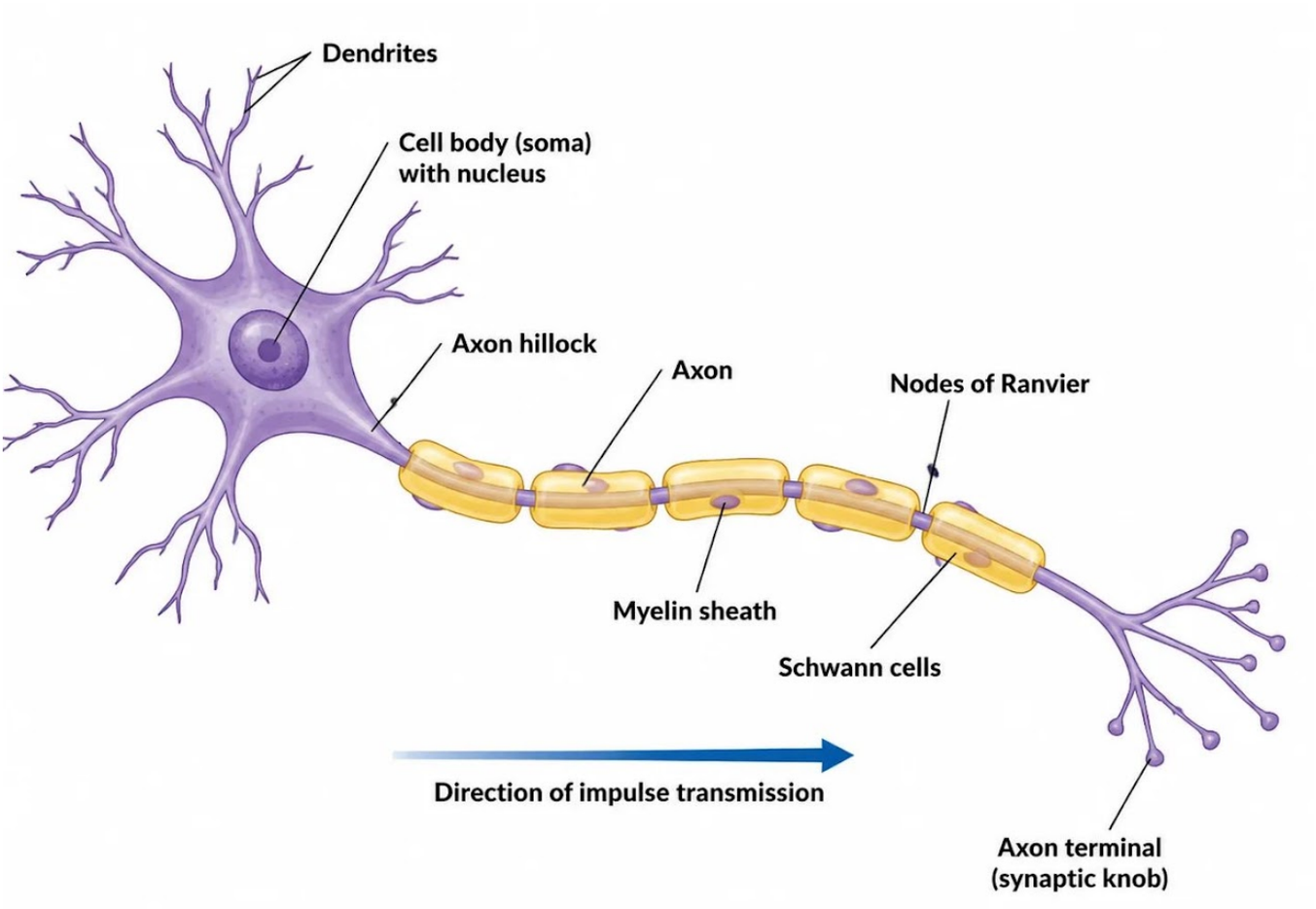

Nervous System - illustration 2

Nurses Content
Downloaded from nursescontent.com

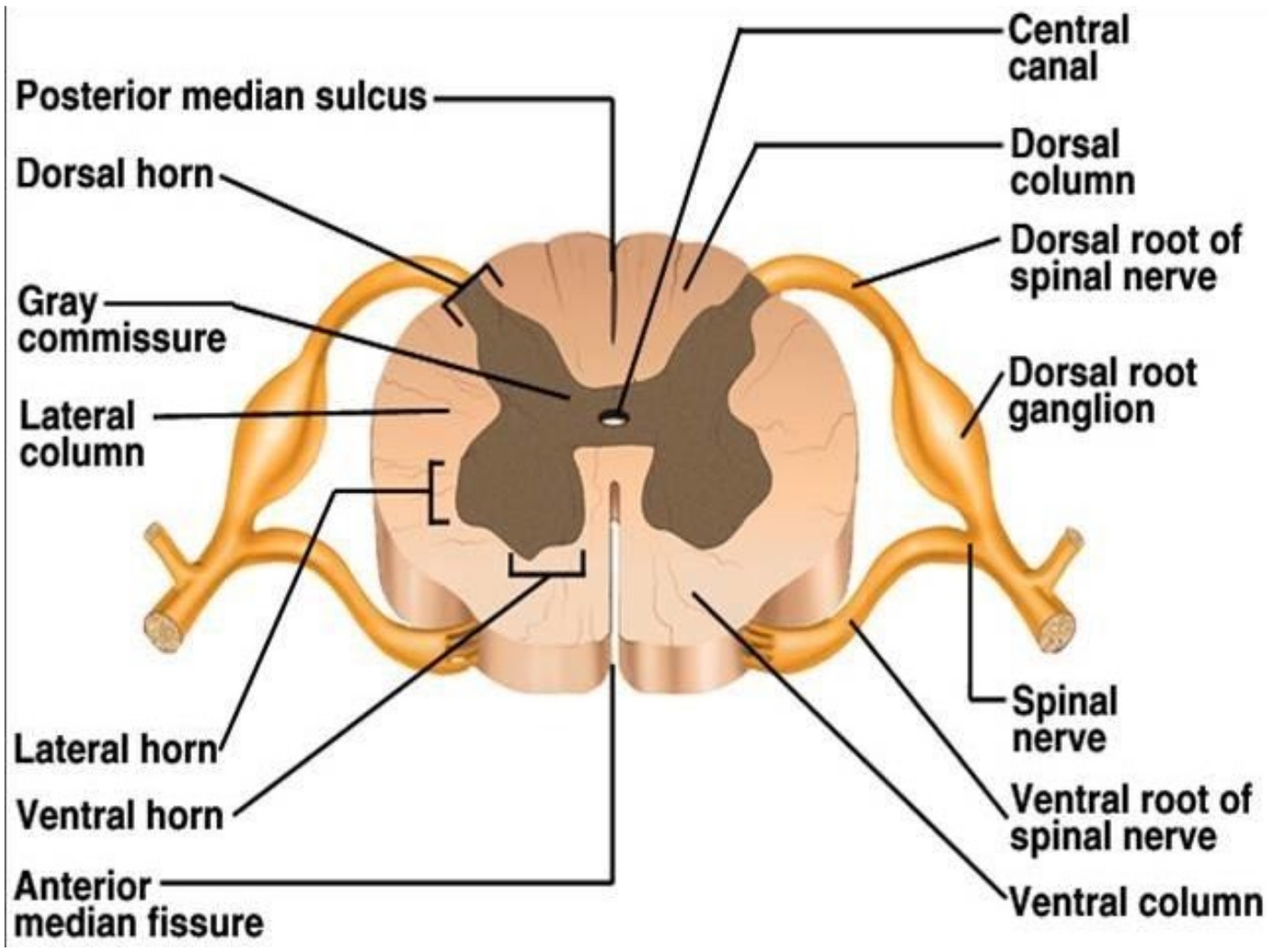

Nervous System - illustration 3

Nurses Content
Downloaded from nursescontent.com

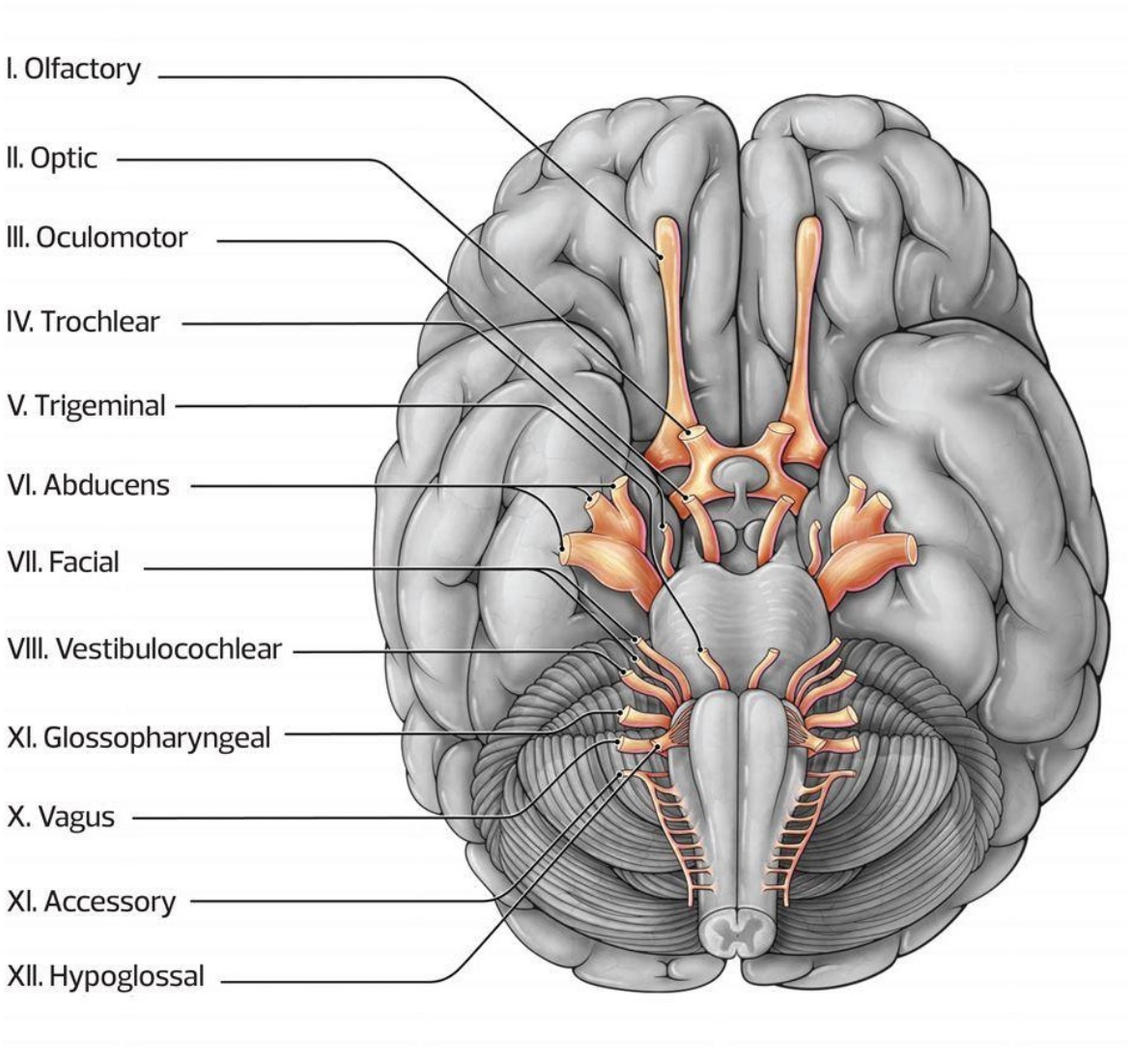

Nervous System - illustration 4

Nurses Content
Downloaded from nursescontent.com

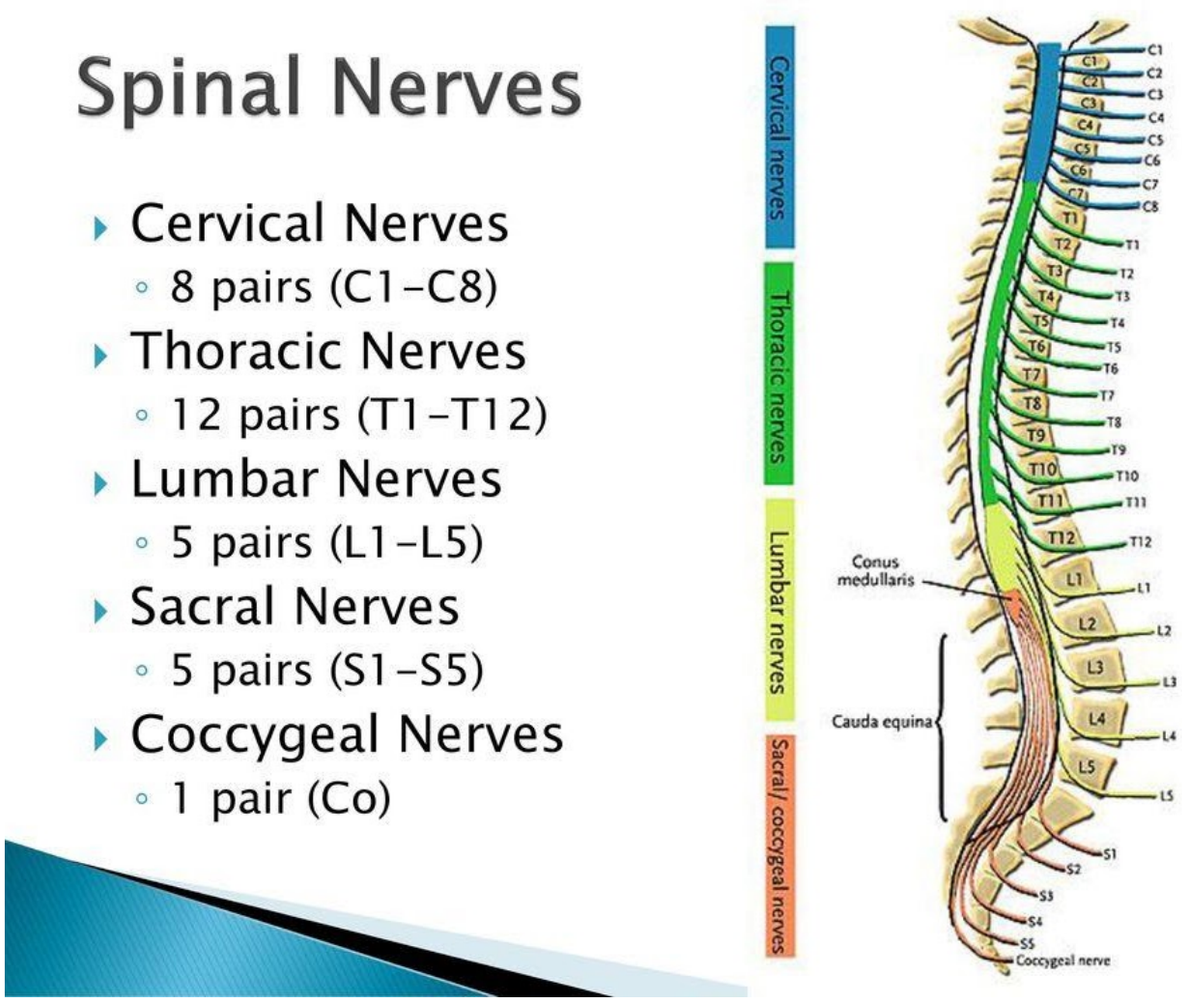

Nervous System - illustration 5

Nurses Content
Downloaded from nursescontent.com

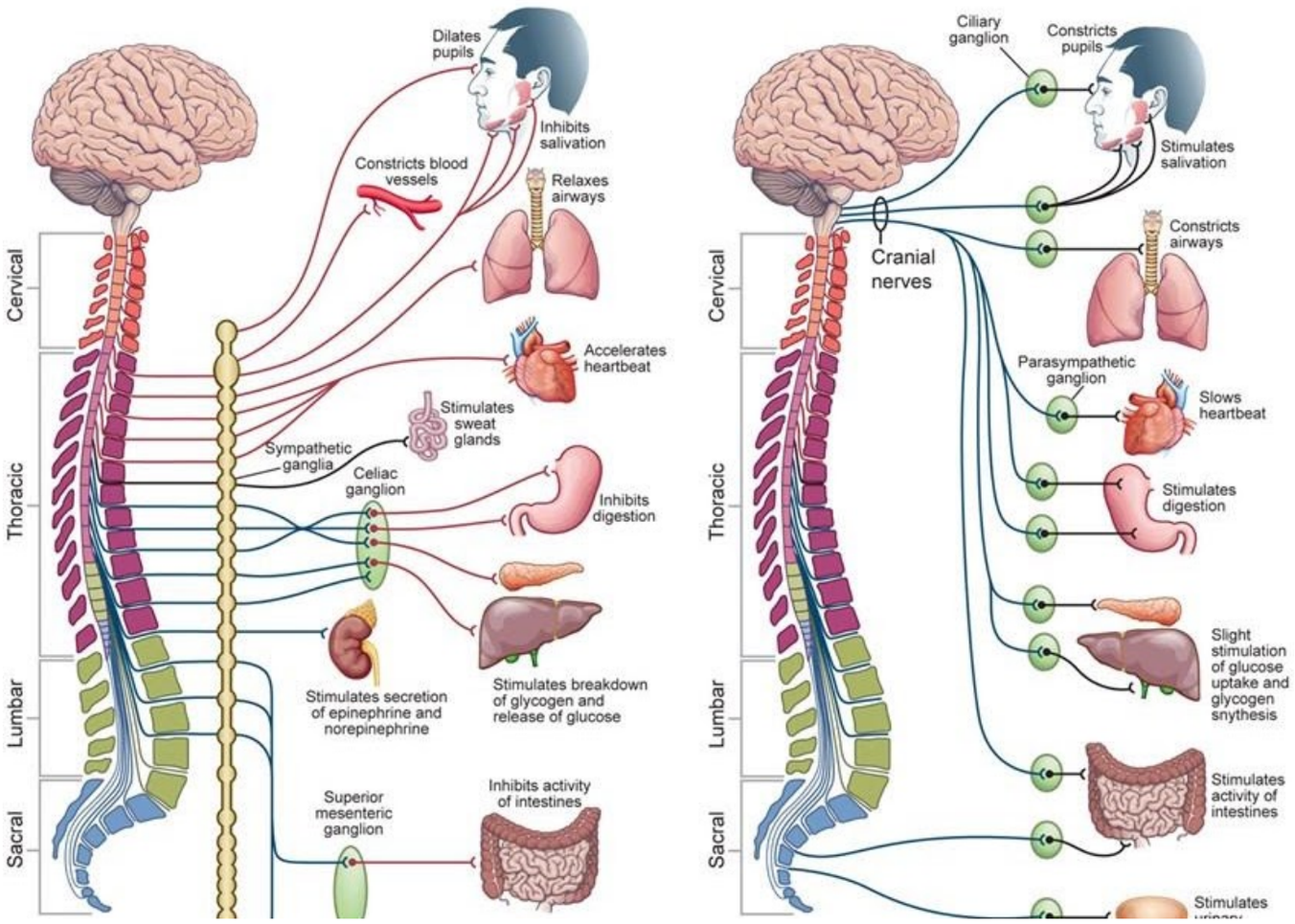

Nervous System - illustration 6

Quick Revision

- Organization & nervous tissue: The central nervous system (CNS) comprises brain and spinal cord. The peripheral nervous system (PNS) includes nerves and ganglia outside the CNS. Neurons have a cell body, dendrites and axon; glial cells support and protect nervous tissue.

- Brain & coverings:

- Spinal cord & nerves: The adult spinal cord usually ends near L1-L2; lower nerve roots form the cauda equina. Central H-shaped grey matter is surrounded by white matter.

- Autonomic divisions & reflex arc: A simple reflex arc includes receptor -> sensory neuron -> CNS integration -> motor neuron -> effector. Autonomic pathways typically use preganglionic and postganglionic neurons.

Examination questions

1. List brainstem components.

2. Name meninges in order.

3. Compare dorsal and ventral roots.

Practice questions

Choose one best answer. The answer key and explanations follow the questions.

Nurses Content
Downloaded from nursescontent.com

1. Which structure belongs to the brainstem?

A. Cerebellum

B. Pons

C. Thalamus

D. Frontal lobe

2. CSF surrounds the CNS in the:

A. Subarachnoid space

B. Subdural space normally

C. Epidural space of the skull

D. Pleural cavity

3. How many pairs of spinal nerves are there?

A. 12

B. 24

C. 31

D. 33

4. Following a left cerebral hemisphere stroke, a patient has weakness of the right arm and leg. Which anatomical relationship best explains this finding?

A. Motor pathways never cross the midline

B. Most corticospinal fibres cross to the opposite side in the lower medulla

C. The cerebellum supplies only the right side of the body

D. The spinal cord has no role in voluntary movement

Nurses Content
Downloaded from nursescontent.com

Answer key and explanations

1. B - Pons

Brainstem comprises midbrain, pons and medulla.

2. A - Subarachnoid space

The subarachnoid space lies between arachnoid and pia.

3. C - 31

There are 31 pairs: 8 cervical, 12 thoracic, 5 lumbar, 5 sacral and 1 coccygeal.

4. B - Most corticospinal fibres cross to the opposite side in the lower medulla

Most corticospinal fibres cross at the pyramidal decussation, so a cerebral lesion above that crossing commonly affects the opposite side.

Source and attribution

Online chapter: https://nursescontent.com/learn/anatomy-physiology/nervous-system/

Downloaded from Nurses Content. Branding identifies the delivery website. Original author credits, third-party licences and applicable rights remain unchanged.